

Objective evaluation for analgesia of the distal interphalangeal joint, the navicular bursa and perineural analgesia in horses with naturally occurring forelimb lameness localised to the foot

Vasiliki Katrinaki¹  | Roberto J. Estrada^{1,2} | Kathrin Mählmann¹ |
Panagiotis Kolokythas³ | Christophorus J. Lischer¹

¹Equine Clinic, Faculty of Veterinary Medicine, Freie Universität Berlin, Berlin, Germany

²Large Animal Hospital, School of Veterinary Medicine, National University, Heredia, Costa Rica

³Service of Statistic AD HOC Studies, Chalkis, Greece

Correspondence

Vasiliki Katrinaki, Equine Clinic, Faculty of Veterinary Medicine, Freie Universität Berlin, Oertzenweg 19b, 14163 Berlin, Germany.
Email: katrinaki@zedat.fu-berlin.de

Present address

Vasiliki Katrinaki, University of Leipzig, Faculty of Veterinary Medicine—Clinic for Horses, An den Tierkliniken 21, Leipzig, Sachsen 014103, Germany

Abstract

Background: The outcome and interpretation of intra-synovial diagnostic analgesia of the distal interphalangeal joint (DIPJ) and the navicular bursa (NB) remain in dispute, and no objective studies have been carried out to establish the percentage of improvement over time from these two analgesia techniques.

Objectives: To investigate the qualitative and time-dependent outcome of DIPJ-A and NB-A in naturally occurring forelimb lameness.

Study design: Case series.

Methods: Twenty-three clinical cases with forelimb lameness were evaluated objectively using a body mounted inertial sensor system (BMIS). Lameness was localised to the foot with a palmar digital nerve block and/or an abaxial sesamoidean nerve block on day 1, and analgesia of the DIPJ (DIPJ-A) and NB (NB-A) were performed on days 2 and 3. Improvement following perineural analgesia was measured after 10 min and intra-synovial blocks after 2-, 5- and 10-min. Horses with at least 70% improvement measured objectively after diagnostic analgesia were included in the study.

Results: There was no significant association between improvement following perineural analgesia and the DIPJ-A and NB-A. The mean improvement in the lameness differed between DIPJ-A and NB-A at 2 min ($p < 0.001$) and at 5 min ($p = 0.04$), and it was no longer observed after 10 min ($p = 0.06$). A positive NB-A produced a high degree of improvement that remained stable, whereas the DIPJ-A improved over time.

Main limitations: Perineural and intra-synovial analgesia were performed without contrast medium to assess the diffusion of mepivacaine.

Conclusions: Our results suggest that perineural analgesia is not reliable enough to differentiate pain originating from DIPJ and NB. Early evaluation of the DIPJ-A and NB-A can determine the origin of the pain. An improvement following NB-A was constant over time, but an improvement following DIPJ-A varied by up to 10 min.

KEYWORDS

horse, intra-synovial analgesia, lameness locator, perineural block

This is an open access article under the terms of the [Creative Commons Attribution-NonCommercial](https://creativecommons.org/licenses/by-nc/4.0/) License, which permits use, distribution and reproduction in any medium, provided the original work is properly cited and is not used for commercial purposes.

© 2022 The Authors. *Equine Veterinary Journal* published by John Wiley & Sons Ltd on behalf of EVJ Ltd.

1 | INTRODUCTION

Pathologies localised to the foot are a common source of lameness in horses with pathologies of the podotrochlear apparatus, accounting for one-third of all chronic forelimb lameness.¹ Despite the fact that heel pain is a common orthopaedic problem, the results of diagnostic analgesia of the equine digit are still disputed. Further differentiation of the source of lameness can be carried out with intra-synovial analgesia. However, investigations about communications between the distal interphalangeal joint (DIPJ) or the navicular bursa (NB) tend to conflict.²⁻⁷

In experimental and clinical studies, the results of analgesia of the DIPJ (DIPJ-A) and NB (NB-A) have been subjectively investigated. Intra-synovial injection of local anaesthetic in the DIPJ did not specifically alleviate pain originating there, but it reduced pain associated with the NB⁸⁻¹⁰ and the sole.¹¹ In contrast, analgesia of the NB was reported to be specific for pathologies of the NB, the navicular bone and its ligaments,⁹ solar toe,¹² or the distal part of the deep digital flexor tendon.^{9,13} When anatomical contrast studies are combined with subjective evaluations, there is no consensus on whether analgesia of the DIPJ and NB are useful in differentiating the source of the pain from these synovial structures.^{10,12,14-16}

Body mounted inertial sensors (BMIS)¹⁷⁻¹⁹ can be used to objectively investigate the effect of local analgesia in lame horses. There is no information in the literature that objectively compares the response to perineural and intra-synovial analgesia of the DIPJ and the NB in clinical cases of forelimb foot pain.

This study aimed to objectively evaluate and compare the response of intra-synovial analgesia of the DIPJ and the NB in clinical cases with forelimb lameness where pain was localised to the foot with perineural analgesia. Improvement in the lameness after the two forms of regional analgesia was compared in different timepoints after the analgesia. We hypothesised that the results of intra-synovial analgesia of the DIPJ and of the NB would be different, reflecting desensitisation of the different compartments within the foot and further hypothesised that there would be an association between the percentage of improvement in the lameness after the DIPJ-A and the NB-A and the time-point of evaluation after the analgesia. An additional hypothesis was that perineural analgesia would not differ in terms of pain originating from DIPJ and NB.

2 | MATERIALS AND METHODS

2.1 | Horses

Horses included in this study were examined for lameness at the Equine Hospital of Freie Universität in Berlin between 2012 and 2016. Inclusion criteria were: (1) presence of a constant primary forelimb lameness when trotting in a straight line during the three-day lameness examination, all horses had to have a comparable amplitude of lameness presenting on the same side during the three-day lameness examination; (2) improvement in the lameness by at least 70% after perineural analgesia (palmar digital nerve block [PDNB] or

abaxial sesamoidean nerve block [ASNB]) or intra-synovial analgesia (DIPJ-A or NB-A), according to BMIS software and (3) the owner's consent to allow the horse to participate in the study. The horses were stabled at the Equine Hospital during the three-day lameness examination.

2.2 | Instrumentation

All of the horses were equipped with a BMIS, the lameness locator (TM: Equinosis[®]) as described in other studies.¹⁷⁻²⁰ The precision and validation of this system has been proven over the years by numerous studies.²¹⁻²³

2.3 | Lameness examination

All of the horses underwent a subjective lameness examination by an experienced veterinarian during the three-day lameness evaluation to confirm the lame leg. Diagnostic analgesia was performed and its percentage of improvement calculated. Objective examination using the BMIS was performed as well to obtain objective data on lameness. In total, five veterinarians carried out the lameness examination, but one conducted the three-day lameness examination for every individual horse. The horses were trotted twice on an even and hard trotting lane (20 m long) by the same person. For each horse, a straight line (baseline) with sufficient strides and a low standard deviation was obtained. After the baseline measurement, which was repeated every day, diagnostic analgesia was performed. Measurements were repeated as described below for each analgesia intervention and compared to the baseline.

On day 1, PDNB was performed¹⁵ with 2 ml of 2% mepivacaine (Scandicain 2%; AstraZeneca GmbH) per site injected using a 25-gauge needle. The injection site was palmar to the neurovascular bundle, immediately above the hoof cartilage, and the needle was orientated distally. Response to analgesia was measured after 10 min. As shown in Table S1, in some cases, an ASNB was performed even if the PDNB was positive according to the BMIS, but the veterinarian (subjectively) decided that the PDNB was negative. The evaluation of diagnostic analgesia and categorisation of the horses into groups were made solely according to the objective assessment of the BMIS. ASNB was performed with 3 ml of 2% mepivacaine per site.¹⁵ A 25-gauge needle orientated distally was inserted at the abaxial borders of the proximal sesamoid bones, palmar to the neurovascular bundle and at the base of the proximal sesamoid bones. Evaluation of the ASNB was performed 10 min after the injection.

Skin sensitivity was assessed using a blunt pinball instrument. Loss of skin sensation on the heels after a PDNB, as well as the coronary band of the dorsal hoof wall after ASNB, was considered to be a correct performance of perineural analgesia. Afterwards, the horses were split into two groups based on the results of the perineural analgesia: PDNB group and ASNB group. Horses with pain localised in the distal limb proceeded to intra-synovial analgesia on day 2 and day 3.

On day 2, DIPJ-A was carried out using the dorsal parallel approach²⁴ with 5 ml of 2% mepivacaine and using a 20-gauge needle. The effect of DIPJ-A was subjectively evaluated after 2, 5, and 10 min and with the BMIS. The presence of synovial fluid was an indication of correct puncture.

On day 3, NB-A was performed using the Verschooten technique as previously described.²⁵⁻²⁷ The injection site was aseptically prepared with polyvinylpyrrolidone-iodine soap (7.5% for 5 min) followed by 70% isopropyl alcohol.²⁸ The limb was then placed on a Hickman block and a subcutaneous injection of 1 ml of 2% mepivacaine was performed using a 25-gauge needle. Three ml of 2% mepivacaine was injected using a 20-gauge (3.5 inch) disposable spinal needle into the NB.^{14,24} The correct needle position was confirmed by a lateromedial x-ray projection. The effect of NB-A was subjectively evaluated after 2, 5 and 10 min and with the BMIS. A flow chart with the study design is shown in Figure 1.

2.4 | Data acquisition and analysis

Data from all the sensors were transmitted wirelessly via Bluetooth to a computer tablet and simultaneously analysed with the software of the motion analysis system.²⁹ The vertical movement of the head in mm was obtained by transforming acceleration into displacement signal. The maximum height differences of the head (Diff.Max Head) and the minimum height differences of the head (Diff.Min Head) between the right and the left halves of the stride were calculated for each stride and then reported as a mean over all strides collected. The evidence of lameness was based on amplitude and the variability of the calculated

lameness variables. Strong evidence was reported when the means of the head were above the threshold value, and the standard deviation (SD) was less than 50% of the mean. Moderate evidence was reported when the SD was between 50% and 120% of the mean, and weak evidence when the SD was greater than 120% of the mean. The total differences of head movement (Total Diff. Head) for forelimbs that represent the total head movement was estimated by the vector sum (VS) and was considered as the amplitude of total head movement asymmetry, considering both the Diff.Max Head and Diff.Min Head. The VS was used to estimate the overall level of forelimb lameness and was calculated manually and automatically by the Pythagorean theorem, $VS = \sqrt{\text{Diff. Max Head}^2 + \text{Diff. Min Head}^2}$ according to the software. Lameness was identified by BMIS based on previously defined thresholds, with the severity of lameness varying from mild to severe. A mild lameness was reported when the VS was $8.5 \text{ mm} \leq VS < 17 \text{ mm}$, a mild/moderate lameness when $17 \text{ mm} \leq VS < 25.5 \text{ mm}$, a moderate lameness when $25.5 \text{ mm} \leq VS < 34 \text{ mm}$ and a moderate/severe lameness when $34 \text{ mm} \leq VS$ (there is no correlation between the lameness metrics of the BMIS and the American Association of Equine Practitioners' lameness grading scale). The side and type of lameness (push off, midstance, impact) were reported based on the positive or negative value of the Diff.Max Head and Diff.Min Head.²⁹⁻³³

The degree of improvement in the lameness after blocking was determined as a percentage decrease of VS from the baseline measurement or $[(VS_{\text{before block}} - VS_{\text{after block}}) / (VS_{\text{before block}} - VS_{\text{threshold}})]$. A decrease in lameness, meaning a decrease in VS, of at least 70% was considered to be a definite positive response to diagnostic analgesia.³⁴ To check if the horses had a comparable degree of lameness (VS) on the same limb on all days of the examination (the side of lameness was

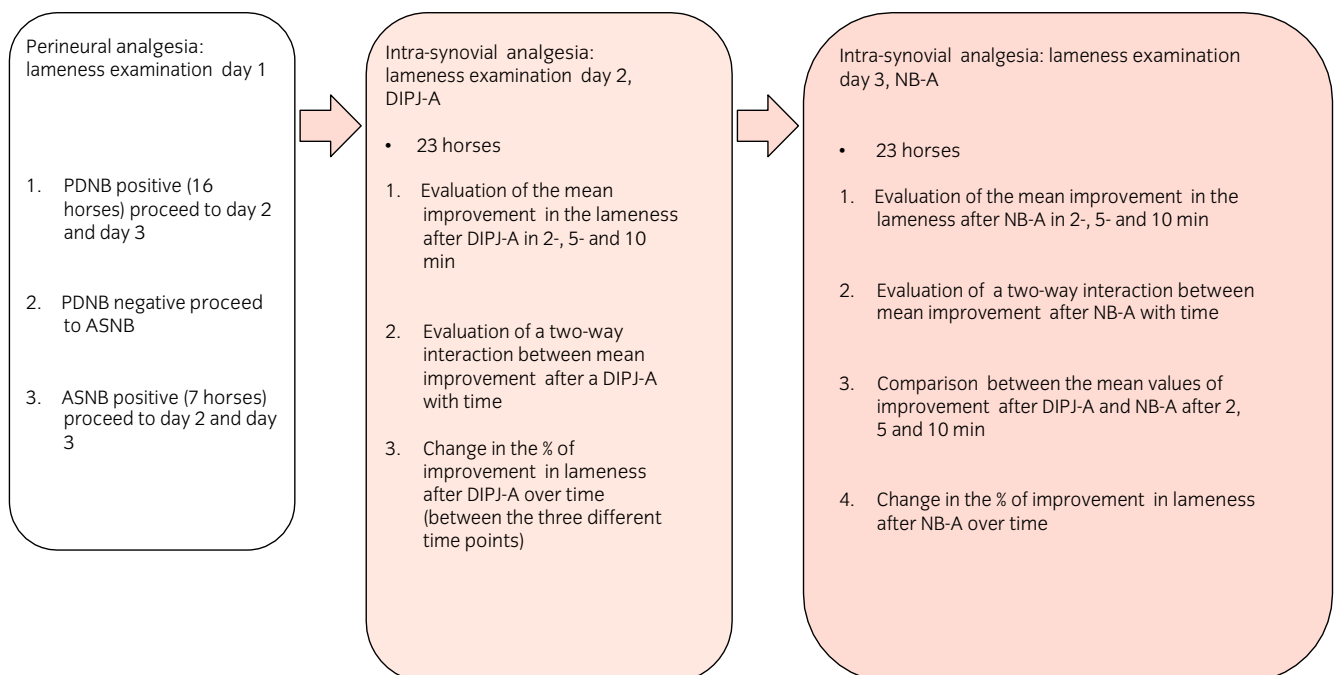


FIGURE 1 Flow chart showing the study design. ASNB, abaxial sesamoidean nerve block; DIPJ-A, intra-synovial analgesia of the distal interphalangeal joint; NB-A, intra-synovial analgesia of the navicular bursa; PDNB, palmar digital nerve block

represented by a negative or positive value of Diff.Min Head),³³ we performed a sign test for VS and a paired t-test for Diff.Min Head. A comparison of Diff.Max Head was also made using a paired t-test.

In some cases, perineural or intra-synovial analgesia eliminated lameness in the anaesthetised limb, but lameness then presented in the opposite forelimb. Subsequently, the VS was above the threshold value, due to a high amplitude of asymmetry in the opposite forelimb. In these cases, the analgesia was considered to have an improvement of 100%.

The Fischer exact test was used to compare the horses in PDNB group to ASNB group, and their relation to the intra-synovial analgesia on day 2 and day 3. McNemar test was used to establish how the horses of PDNB group responded to intra-synovial analgesia on day 2 and day 3. Due to the small sample of horses in the ASNB group, the comparison to intra-synovial analgesia on day 2 and day 3 was descriptive.

Two-way repeated ANOVA was performed to investigate a two-way interaction between mean improvement after DIPJ-A and NB-A with time. A one-way ANOVA test was performed to test for a difference between the mean improvement of DIPJ-A and NB-A at each time-point, and a non-parametric test (Sign test) to confirm the results. In order to examine how the horses reacted on day 2 (DIPJ-A) and day 3 (NB-A), we used a one-way ANOVA (simple main effects) and a Friedman test to confirm the results with a non-parametric alternative.

3 | RESULTS

Twenty-three horses met the inclusion criteria: 20 Warmbloods, 2 quarter horses and 1 pony. The age varied between 4 and 16 years (mean, 11.5 years). The majority of horses (21/23) had strong evidence of forelimb baseline lameness, and 2/23 horses had moderate evidence of lameness in one aspect of the baseline examination. The side and the degree of the baseline lameness remained the same for all 3 days with the type of lameness only changing between day 1 and day 2. Lameness according to the BMIS scale was categorised as mild to severe.

3.1 | Perineural analgesia: Lameness examination day 1

Sixteen horses had objectively positive following PDNB and 7 horses following positive ASNB on day 1 (Table S1).

3.2 | Outcome of intra-synovial analgesia in relation to perineural analgesia

The PDNB group included 16 horses, whereas the ASNB group comprised of 7 horses. There was no statistically significant difference between the PDNB group and the ASNB group in the number of horses that improved after DIPJ-A or NB-A ($p > 0.05$) (Figure 2).

Comparison of the horses in the PDNB group with intra-synovial analgesia showed that in assessments after 2 min there was a statistically significant difference in the number of horses with positive analgesia following NB injections (10/15 [67%]) compared to DIPJ-A (3/15 [20%]), $p = 0.02$. The number of horses included in the 2 min assessments was 15, because horse n.20 did not have NB-A measurement after 2 min (Table S1). For the assessments after 5 min ($p = 0.07$) and 10 min ($p = 0.1$) there was no statistical significance regarding the number of horses that improved following DIPJ-A and NB-A.

Comparison of the group ASNB to intra-synovial analgesia was descriptive because the number of the horses in this group was small and no statistical analysis could be performed. After 2 min, 3/6 (50%) of the horses had a positive DIPJ-A and 5/7 (71.4%) of the horses had a positive NB-A. After 5 min, 3/7 (42.9%) of the horses had positive DIPJ-A and 3/7 (42.9%) of the horses had a positive NB-A. After 10 min, 2/6 (33.3%) of the horses had a positive DIPJ-A and 4/7 (57.1%) of the horses had a positive NB-A (the horse n.12 did not have a valid measurement of DIPJ-A after 2- and 10 min [Table S1]).

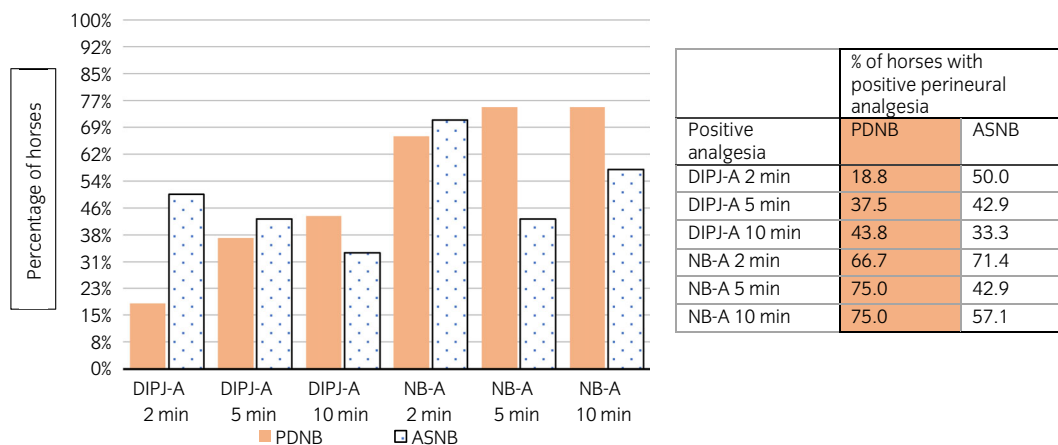


FIGURE 2 Comparison of responses to intra-synovial diagnostic analgesia of the distal interphalangeal joint (DIPJ-A) and the navicular bursa (NB-A) in horses with positive to perineural anaesthesia of the palmar digital nerve (PDNB) and abaxial sesamoidean nerve (ASNB) in horses with forelimb foot pain

TABLE 1 Impact of time on mean values of improvement in the lameness following intra-synovial diagnostic analgesia of the distal interphalangeal joint (DIPJ-A) and the navicular bursa (NB-A) in horses with forelimb foot pain

Analgesia	Time (min)	% mean improvement	Standard error	95% confidence interval	
				Lower bound	Upper bound
DIPJ-A	2	31.69	7.99	15.8	49.14
	5	47.78	9.32	26.54	65.42
	10	55.59	8.267	37.28	71.77
NB-A	2	75.36	6.82	62.70	91.15
	5	74.51	7.19	62.1	92.08
	10	73.72	7.7	59.05	91.17

3.3 | Intra-synovial analgesia: Lameness examination day 2 and 3

There was a statistically significant two-way interaction between analgesia and time, ($p = 0.02$). The mean improvement of DIPJ-A and NB-A depended on the point in time at which the horses were assessed (after 2, 5 or 10 min). There was a statistically significant difference in the mean improvement between DIPJ-A and NB-A at 2 min (one way ANOVA $p < 0.001$, Sign test $p < 0.001$) and 5 min (one way ANOVA $p = 0.04$, Sign test $p = 0.03$) after injection, but not after 10 min (one way ANOVA $p = 0.06$, Sign test $p = 0.05$). Evaluation of the DIPJ-A overtime revealed a significant difference between 2-min and 10-min measurements (ANOVA pairwise comparison $p = 0.04$, Friedman $p = 0.00$). There was no statistically significant difference in improvement after NB-A at 2, 5- and 10-min (ANOVA test of within-subjects effect $p = 0.929$, Friedman $p = 0.39$) (Table 1).

4 | DISCUSSION

This is the first study to objectively analyse the response to intra-synovial analgesia of the DIPJ and NB over time and in relation to perineural analgesia in horses with naturally occurring forelimb lameness. There was no difference between the PDNB group and the ASNB group in the number of horses that improved after DIPJ-A or NB-A, suggesting that response to perineural analgesia is not a reliable method to predict the outcome of intra-synovial analgesia. Our results agree with another study based on the objective assessment of PDNB and ASNB in relation to DIPJ-A, where no difference was found between the PDNB group and the ASNB group in the number of horses that improved after DIPJ-A.¹⁷ In an experimental study, lameness induced by injecting lipopolysaccharid into the DIPJ was alleviated by PDNB. According to this study, the dorsal branches of the palmar digital nerve remain superficial and probably innervate the dorsal aspect of the coronary band and the dorsal laminae of the foot without playing a major role in the innervation of the DIPJ.³⁵ Anaesthetic solution can diffuse proximally after performing a PDNB. Although the needle was oriented distally and exactly proximal to the hoof cartilages in this study, 2 ml of mepivacaine instead of 1.5 ml were used.^{36,37}

Assessment of perineural analgesia of the equine digit usually takes place between 5 and 10 min. The onset of analgesia with mepivacaine depends on multiple factors such as the proximity of the local anaesthetic to the nerve, the dose and the properties of the anaesthetic solution, the size of the nerves and the characteristics of the tissue.^{38,39} In the literature, the effect of the perineural analgesia of the digit is sometimes assessed after 5 min, pointing out that an earlier assessment can lead to false negative results and a later examination may decrease accuracy due to diffusion.^{26,34} On the other hand, maximum diffusion of contrast medium was observed 10 min after the PDNB. The observation of contrast medium led to the speculation that the distribution of the local anaesthetic outside of the fascia of the neurovascular bundle or in lymphatic vessels may cause a delay or a decreased effect of the nerve block.³⁷ Clinical observations suggest that it can take up to 10 min for the local anaesthetic to have an effect after a PDNB. So far, there is no evidence that after perineural analgesia of the distal limb, there is a difference in improvement in the lameness between 5- and 10-min. Here, we decided to evaluate the perineural analgesia after 10 min to avoid false negative results.

In the PDNB group, there was a significant difference in the number of horses that improved with an NB-A after 2 min compared to the number of horses that improved with a DIPJ-A after 2 min. Our study confirmed what has been previously observed, namely that the PDNB cannot efficiently differentiate pain from the DIPJ and the NB,^{9,11} and only a very rapid assessment (2 min) of the DIPJ-A and the NB-A can correspond to the results of the PDNB.

The mean values of improvement after DIPJ-A and NB-A were compared after 2, 5, and 10 min. The comparison of DIPJ-A and NB-A based on these three time points showed that there was a statistically significant difference between the mean improvement in the lameness at 2 and 5 min assessments after diagnostic analgesia. According to these results, the assessment of DIPJ-A and NB-A should be performed at 2 and 5 min to observe a difference in improvement between the two analgesia.

Comparisons for the DIPJ-A on day 2 and for the NB-A on day 3 were performed separately for different points in time to observe how each analgesia develops over time. In this study, 60% of the positive DIPJ-A cases already showed a positive response after 2 min, however, horses reached the maximum percentage of mean improvement within 10 min. This dynamic was different for NB-A, whereby

88% of the positive NB-A horses already showed a positive response after 2 min and more than half of the cases with a positive NB-A experienced a 100% improvement in the lameness after 2 min. Furthermore, 12% of the horses showed a positive response after 5 min and 10 min, highlighting that there are no distinctive differences in the effectiveness of this block for up to 10 min.

The optimal time to assess a DIPJ-A has already been subjectively investigated. According to the literature, a full effect of the DIPJ-A and improvement in the lameness is expected after 5 min^{8,17,40} or 20 min.^{9,14}

Based on the aforementioned results, the points in time at which diagnostic analgesia should be assessed are essential after intra-synovial analgesia, as the accuracy of the pain location may decrease over time. This could be a result of the diffusion of the local anaesthetic solution to the surrounding nerves.^{14,35}

The sensory nerve fibres on the borders of the dorsal and palmar surface of the collateral sesamoidean ligament (CSL) and the nerves of the distal impar sesamoidean ligament (DSIL) are most likely to be desensitised after a DIPJ-A.⁴¹ The contact site of the palmar pouches of the DIPJ to the palmar digital nerves is proximal to the deep branches innervating the DIPJ and NB.

Diffusion from the NB can also desensitise the deep branches of the palmar digital nerve that innervate the DIPJ. Onset of anaesthesia takes longer because the contact site between the NB and the palmar digital nerves is distal to the aforementioned deep branches.¹⁴

This could explain why even within 10 min of a DIPJ-A there is no significant difference between DIPJ-A and NB-A. Another possible explanation for this result is that the diffusion of anaesthetic is different between the DIPJ and NB. The concentrations of mepivacaine in the NB after the injection of the DIPJ are usually higher, rather than vice versa.¹⁶

In this study, more horses had a positive NB-A than a DIPJ-A. One possible explanation for this outcome is that the majority of the horses could have had a pathology in the navicular apparatus or the fact that the NB as a smaller synovial structure with rich sensory innervation, needs less time to be desensitised in relation to the DIPJ. A negative response to intra-articular analgesia of the DIPJ should not rule out pathologies of the navicular bone and its related structures as the cause of pain.

5 | LIMITATIONS OF THE STUDY

In most cases, a complete lameness examination involves an assessment of the horse while lungeing the horse in a circle. In this study, objective data were only derived from straight line trotting assessments. Perineural and intra-synovial analgesia were performed without contrast medium to assess the diffusion of mepivacaine. We were concerned that this could have led to unrealistically high volumes of solutions and different viscosity compared to the clinical practice.^{10,16} Furthermore, the correct needle position in NB-A was

evaluated by a lateromedial x-ray projection but without injecting a contrast medium, because we would not have been able to take repeated radiographs and punctually assess the horses while trotting at 2, 5 and 10 min.

This study investigated the association of perineural and intra-synovial analgesia and the associated response dynamics. This reflects the situation of a clinical lameness assessment in which a diagnosis has yet to be found. However, it would have been interesting to look at how the results of analgesia correlate to a final diagnosis. Magnetic resonance imaging is the golden standard for diagnosing foot pain and not all horses had a definite diagnosis based on recommended imaging modalities, therefore such an analysis was not possible.

6 | CONCLUSIONS

The perineural analgesia was not a reliable method to differentiate pain between the DIPJ and the NB. The results of analgesia of the NB-A and DIPJ-A were different early on (at 2 and 5 min) after injection. Improvement of DIPJ-A increased over time up to 10 min, whereas an improvement of NB-A was constant over time. Evaluation after intra-synovial analgesia should be performed at 2 and 5 min after injection to register a potential difference of both analgesia and to help differentiate between the sources of the pain.

AUTHOR CONTRIBUTIONS

Vasiliki Katrinaki contributed to study design, study execution, and data analysis and interpretation. Roberto J. Estrada contributed to study execution, and preparation of the manuscript. Kathrin Mählmann contributed to the preparation of the manuscript. Panagiotis Kolokythas contributed to data analysis and interpretation, and statistical analysis. Christophorus J. Lischer contributed to study design, study execution, and preparation of the manuscript. All authors gave their final approval of the manuscript. Vasiliki Katrinaki had full access to all of the data and takes responsibility for the integrity and accuracy of the data in this study.

ACKNOWLEDGEMENTS

We thank all the veterinarians of the Equine Hospital of Freie Universität in Berlin for the case selection and collaboration. This study is dedicated to my parents.

FUNDING INFORMATION

None.

CONFLICT OF INTEREST

No competing interests have been declared.

PEER REVIEW

The peer review history for this article is available at <https://publons.com/publon/10.1111/evj.13583>.

DATA AVAILABILITY STATEMENT

The data that support the findings of this study are available from the corresponding author upon reasonable request.

ETHICS STATEMENT

Research ethics committee oversight not currently required by this journal: the study was performed on data collected during clinical procedures.

INFORMED CONSENT

All horses had client consent for participation in the study.

ORCID

Vasiliki Katrinaki  <https://orcid.org/0000-0002-3858-8837>

REFERENCES

- Colles C. Navicular disease and its treatment. *In Pract.* 1982;4(2):29–36.
- Gibson K, McIlwraith CW, Park R. A radiographic study of the distal interphalangeal joint and navicular bursa of the horse. *Vet Radiol.* 1990;31:22–5.
- Jann H, Henry G, Berry A, Cash L. Arthrographic observations of the equine distal interphalangeal joint (Articulationes Interphalangeae Distalis Manus) and navicular bursa (Bursa Podotrochlearis). *Anat Histol Embryol.* 1991;20(1):30–6.
- Bowker RM, Rockershouser SJ, Vex KB, Sonea IM, Caron JP, Kotyk R. Immunocytochemical and dye distribution studies of nerves potentially desensitized by injections into the distal interphalangeal joint or the navicular bursa of horses. *J Am Vet Med Assoc.* 1993;203(12):1708–14.
- Borges EM, de Souza MV, de Paula TAR. Anatomical study of the innervation of the distal portion of the thoracic limb in horse. *Cienc Rural.* 1997;27(1):67–73.
- Manfredi JM, Boyce M, Malone ED, Anderson C, Anderson LB, Trumble TN. Steroid diffusion into the navicular bursa occurs in horses affected by palmar foot pain. *Vet Rec.* 2012;171(25):642.
- Hontoir F, Rejas E, Falticeanu A, Nisolle JF, Simon V, Nicaise C, et al. Communication between the distal interphalangeal joint and the navicular bursa in the horse at computed tomography arthrography. *Anat Histol Embryol.* 2019;48(2):133–41.
- Pleasant RS, Moll HD, Ley WB, Lessard P, Warnick LD. Intra-articular anesthesia of the distal interphalangeal joint alleviates lameness associated with the navicular bursa in horses. *Vet Surg.* 1997;26(2):137–40.
- Dyson SJ, Kidd L. A comparison of responses to analgesia of the navicular bursa and intra-articular analgesia of the distal interphalangeal joint in 58 horses. *Equine Vet J.* 1993;25:93–8.
- Keegan KG, Wilson DA, Kreeger JM, Ellersieck MR, Kuo KC, Li Z. Local distribution of mepivacaine after distal interphalangeal joint injection in horses. *Am J Vet Res.* 1996;57(4):422–6.
- Schumacher J, Steiger R, Schumacher J, De Graves F, Schramme M, Smith R, et al. Effects of analgesia of the distal interphalangeal joint or palmar digital nerves on lameness caused by solar pain in horses. *Vet Surg.* 2000;29(1):54–8.
- Schumacher J, Schumacher J, Graves D, Schramme M, Smith R, Coker M, et al. A comparison of the effects of local analgesic solution in the navicular bursa of horses with lameness caused by solar toe or solar heel pain. *Equine Vet J.* 2001;33(4):386–9.
- Schumacher J, Schumacher J, Schramme MC, De Graves FJ, Smith R, Coker M. Diagnostic analgesia of the equine forefoot. *Equine Vet J.* 2004;16(3):159–65.
- Schumacher J, Schumacher J, Gillette R, Graves D, Schramme M, Smith R, et al. The effects of local anaesthetic solution in the navicular bursa of horses with lameness caused by distal interphalangeal joint pain. *Equine Vet J.* 2003;35(5):502–5.
- Schramme MC, Schumacher J, De Graves FJ. Diagnostic analgesia of the equine digit. *CE.* 2013;25(8):408–21.
- Gough MR, Mayhew IG, Munroe GA. Diffusion of mepivacaine between adjacent synovial structures in the horse. Part 1: forelimb foot and carpus. *Equine Vet J.* 2002;34(1):80–4.
- Rungsri PK, Staecker W, Leelamankong P, Estrada RJ, Schulze T, Lischer CJ. Use of body-mounted inertial sensors to objectively evaluate the response to perineural analgesia of the distal limb and intra-articular analgesia of the distal interphalangeal joint in horses with forelimb lameness. *J Equine Vet.* 2014;34(8):972–7.
- Leelamankong P, Estrada RJ, Rungsri P, Wolfgang S, Müller CDVS, Lischer CJ. Objective evaluation of the response to perineural analgesia of the deep branch of the lateral plantar nerve and intra-articular analgesia of the tarsometatarsal joint in horses with suspected proximal metatarsal pain using body-mounted inertial sensors. *J Equine Vet.* 2018;1-18:91–5. <https://doi.org/10.1016/j.jevs.2018.07.004>
- Maliye S, Voute L, Marshall JF. Naturally-occurring forelimb lameness in the horse results in significant compensatory load redistribution during trotting. *Vet J.* 2015;204(2):208–13.
- T Laurie. USER MANUAL Lameness Locator 2017. 2017; 7–9
- Keegan KG, Yonezawa Y, Pai PF, Wilson DA, Kramer J. Evaluation of a sensor-based system of motion analysis for detection and quantification of forelimb and hind limb lameness in horses. *Am J Vet Res.* 2004;48(5):608–12. <https://doi.org/10.1111/evj.12491>
- Maliye S, Voute L, Lund D, Marshall JF. An inertial sensor-based system can objectively assess diagnostic anaesthesia of the equine foot. *Equine Vet J.* 2013;45(Suppl. 45):26–30.
- Keegan KG, MacAllister CG, Wilson DA, Gedon AC, Kramer J, Yonezawa Y, et al. Comparison of an inertial sensor system with a stationary force plate for evaluation of horses with bilateral forelimb lameness. *Am J Vet Res.* 2012;73(3):368–74.
- Moyer W, Schumacher J, Schumacher J. A Guide to equine injection and regional anesthesia; Yardley, PA: Veterinary Learning Systems; 2009. p. 1–110.
- Verschooten F, Desmet P, Peremans K, Picavet T. Navicular disease in the horse: the effect of controlled intrabursal corticoid injection. *J Equine Vet.* 1990;10(4):316–20.
- Moyer W, Schumacher J, Schumacher J. Equine joint injection and regional anesthesia; Yardley, PA: Veterinary Learning Systems; 2013. p. 1–143.
- Schramme MC, Boswell JC, Hamhoughias K, Toulson K, Viitanen M. An in vitro study to compare 5 different techniques for injection of the navicular bursa in the horse. *Equine Vet J.* 2000;32(3):263–7.
- Zubrod CJ, Farnsworth KD, Oaks JL. Evaluation of arthrocentesis site bacterial flora before and after 4 methods of preparation in horses with and without evidence of skin contamination. *Vet Surg.* 2004;33(5):525–30. <https://doi.org/10.1111/j.1532-950X.2004.04074.x>
- Keegan KG, Kramer J, Yonezawa Y, Maki H, Pai F, Dent EV, et al. Assessment of repeatability of a wireless, inertial sensor-based lameness evaluation system for horses. *Am J Vet Res.* 2011;72(9):1156–63.
- Keegan KG, Dent EV, Wilson DA, Janicek J, Kramer J, LaCarrubba A, et al. Repeatability of subjective evaluation of lameness in horses. *Equine Vet J.* 2010;42(2):92–7.
- Keegan KG, Wilson DA, Kramer J, Reed SK, Yonezawa Y, Maki H, et al. Comparison of a body-mounted inertial sensor system-based method with subjective evaluation for detection of lameness in horses. *Am J Vet Res.* 2013;74(1):17–24.
- Tyrrell-Schroeder L. Straight line AIDEs: a detailed look at evidence and amplitude; Broadway, CO: online article by Equinosis; 2018. p. 1–3.

33. Tyrrell-Schroeder L. USER MANUAL Lameness Locator 2016. LL2016, v.1.0 2016, 24–30
34. Ross MW. In: Dyson S, editors. *Diagnosis and Management of Lameness in the horse*. 2nd ed.; Louis, MO: ELSEVIER SAUNDERS; 2011: Chapter 10. p. 100–107.
35. Easter JE, Watkins JP, Stephens SL, Carter GK, Hauge BA, Dutton DW, et al. Effects of regional anesthesia on experimentally induced coffin joint synovitis. *Proc AAEP*. 2000;46:214–6.
36. Schumacher J, Livesey L, Graves FJ, Schramme MC, Hathcock J, Taintor J, et al. Effect of anaesthesia of the palmar digital nerves on proximal interphalangeal joint pain in the horse. *Equine Vet J*. 2004; 36(5):409–14.
37. Nagy A, Bodó G, Dyson SJ, Szabo F, Barr ARS. Diffusion of contrast medium after perineural injection of the palmar nerves: an in vivo and in vitro study. *Equine Vet J*. 2009;41(4):379–83.
38. Covino BG. Clinical pharmacology of local anesthetic agents. In: Cousins MJ, Bridenbaugh PO, editors. *Neural blockade in clinical anesthesia and Management of Pain*. 2nd ed. Philadelphia: J.B. Lippincott Co; 1988. p. 111–44.
39. Salinas FV, Malik K, Benzon HT. Local anesthetics for regional anesthesia and pain management. In: Benzon H, Rathmell JP, Wu CL, Turk DC, Argoff CE, editors. *Raj's practical management of pain*. Philadelphia: Mosby Elsevier; 2008. p. 811–38.
40. Dyson SJ. Lameness due to pain associated with the distal interphalangeal joint: 45 cases. *Equine Vet J*. 1991;23(2):128–35. <https://doi.org/10.1111/j.2042-3306.1991.tb02737.x>
41. Bowker RM, Linder K, Van Wulfen KK, Perry RL, Ocello PJ. Distribution of local anesthetics injected into the distal interphalangeal joint and podotrochlear bursa: an experimental study. *Pferdeheilkunde*. 1996;12:1–4.

SUPPORTING INFORMATION

Additional supporting information may be found in the online version of the article at the publisher's website.

How to cite this article: Katrinaki V, Estrada RJ, Mählmann K, Kolokythas P, Lischer CJ. Objective evaluation for analgesia of the distal interphalangeal joint, the navicular bursa and perineural analgesia in horses with naturally occurring forelimb lameness localised to the foot. *Equine Vet J*. 2023;55(2): 253–60. <https://doi.org/10.1111/evj.13583>