



Diagnostic Exercise

From the Latin Comparative Pathology Group and the Davis-Thompson Foundation

Parvovirus in a margay (*Leopardus wiedii*)

Juan Diego Hidalgo Dittel¹, Roger Such Basiana², Laura G. Bass^{3,4,6}, Gaby Dolz-Wiedner⁵,
Antony Solórzano-Morales⁵, Roberto W. I. Olivares^{1,6*}

¹Servicio de Patología Diagnóstica LAPAVET-ESFA, Cátedra de Patología e Histología, Escuela de Medicina y Cirugía Veterinaria San Francisco de Asís, Universidad Veritas, Vázquez de Coronado, San José, Costa Rica. ²Jaguar Rescue Center, Puerto Viejo, Limón, Costa Rica. ³Maestría en Enfermedades Tropicales, Posgrado Regional en Ciencias Veterinarias Tropicales (PCVET), Universidad Nacional (UNA), Heredia, Costa Rica. ⁴Cátedra de Microbiología e Inmunología, Escuela de Medicina y Cirugía Veterinaria San Francisco de Asís, Universidad Veritas, Vázquez de Coronado, San José, Costa Rica. ⁵Laboratorio de Zoonosis y Entomología, Escuela de Medicina Veterinaria, Universidad Nacional (UNA), Heredia, Costa Rica. ⁶Current position: California Animal Health & Food Safety Laboratory System – UC Davis.

*Corresponding author: rwolivares@ucdavis.edu

Submitted: August 12, 2025. Accepted: August 19, 2025.

Clinical History: Multiple tissue samples from various organs of a juvenile margay (*Leopardus wiedii*) were collected during necropsy. Before death, the animal exhibited severe weakness, vomiting, diarrhea, dehydration, abdominal discomfort, and marked leukopenia.

Autopsy Findings and Microscopic Findings: As reported by the referring veterinarian, autopsy findings revealed a poor body condition with notably pale mucous membranes. Figure 1 shows the only gross alteration seen at autopsy.

Follow-up questions:

- Morphologic gross diagnoses (Fig. 1).
- Histopathologic description and morphologic diagnosis (Fig. 2 and 3).
- Name of the disease.

ANSWERS

1. Morphologic gross diagnoses

- Necrotizing enteritis, diffuse, severe.
- Necrotizing lymphadenitis, diffuse, severe.

*The Diagnostic Exercises are an initiative of the Latin Comparative Pathology Group (LCPG), the Latin American subdivision of The Davis-Thompson Foundation (DTF). These exercises are contributed by members and non-members from any country of residence.

Consider submitting an exercise! A final document containing this material with answers and a brief discussion will be posted on the DTF website:
<https://davisthompsonfoundation.org/diagnostic-exercise/>

Editor-in-chief for this Diagnostic Exercise: Claudio Barros
Associate Editor for this Diagnostic Exercise: Francisco A. Uzal



2. Histopathologic description.

Small intestine: The mucosal architecture of the small intestine was diffusely distorted due to marked villous atrophy and fusion, with segmental loss of villi and crypts. Affected areas displayed dilated crypts replaced by cellular debris and mild inflammatory infiltrates of lymphocytes and plasmacytes in the lamina propria. Remaining crypts were dilated, filled with necrotic epithelial cells, and often lined by attenuated epithelium. Necrotic crypts contained sloughed enterocytes and cellular debris. (Fig. 3).

The intestinal surface exhibits severe ulceration, associated with fibrin exudation, a mild neutrophilic infiltrate, hemorrhage, and numerous colonies of small bacilli-shaped bacteria (Fig. 2 and 4).

Additionally, the lymphoid tissue in Peyer's patches and mesenteric lymph nodes demonstrated severe lymphocytic depletion accompanied by necrosis.

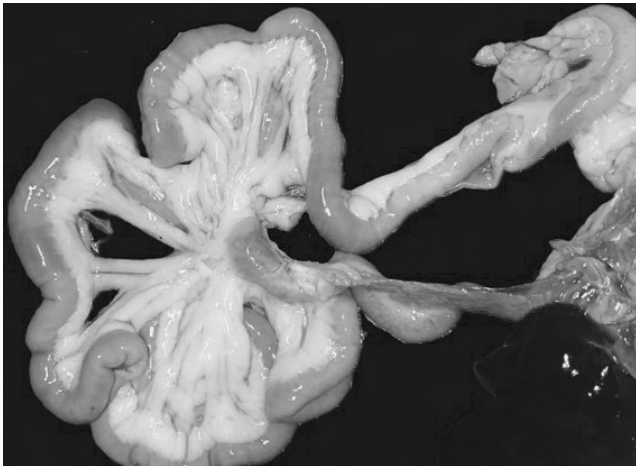


Figure 1. Severe mesenteric lymphadenomegaly (white arrow) and necrotizing enteritis.

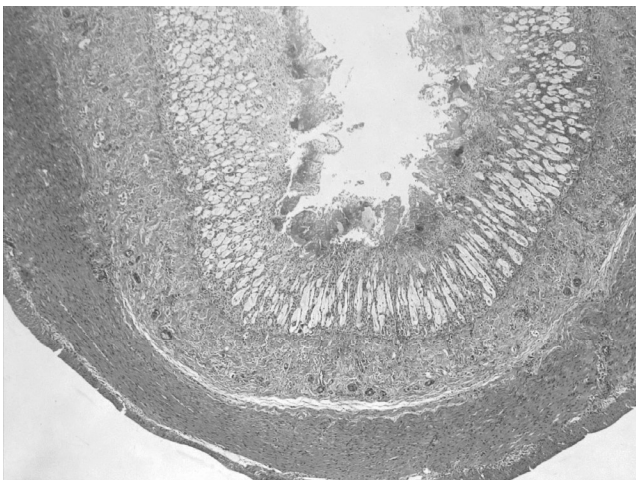


Figure 2. Enteritis, necrotizing, fibrinous, diffuse, severe, with villus blunting. 100X, H&E.

3. Morphologic Diagnosis: Severe, acute, segmental, necrotizing and fibrinosuppurative enteritis with crypt necrosis, and villous atrophy and blunting.

4. Name of the Disease: Parvovirus

Comments:

The viral lesions of the small intestine, as well as the severe lymphoid depletion observed in the lymph node and Peyer's patches, are compatible with a parvovirus infection. The necrotizing lesions observed in the apical part of the intestinal mucosa could be associated with a bacterial etiology, which would have been triggered secondary to the

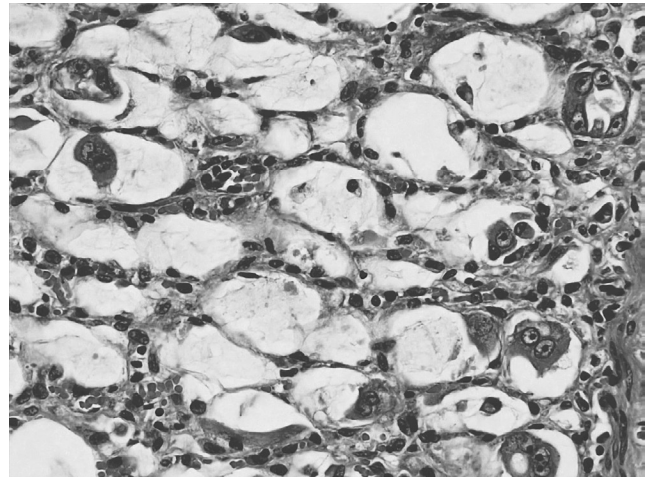


Figure 3. Small intestine, Lieberkühn crypts: dilated crypts with intraluminal cellular debris, mild lymphoplasmacytic inflammation, and severe attenuation of the epithelium. 400X, H&E.

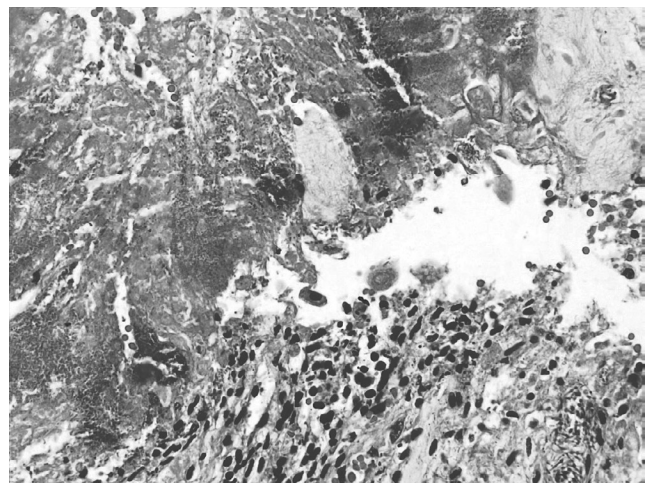


Figure 4. Small intestine, surface epithelium: severe ulceration of luminal surface with loss of villus, fibrin deposition, scarce neutrophils, and bacteria. 400X, H&E.

immunosuppression caused primarily by the virus. DNA was extracted from paraffin-embedded tissues (small intestine and lymph node). Real-time PCR for carnivore protoparvovirus 1 (CPPV-1) was positive (Ct 38.48), detecting a 99 bp fragment of the VP2 gene. To differentiate between CPPV-1 variants (feline panleukopenia virus [FPL] and canine parvovirus type 2 [CPV-2], including variants CPV-2a, CPV-2b, and CPV-2c), a nested PCR targeting the VP2 gene was performed (1). However, all samples tested negative, most likely due to the low DNA yield from the paraffin-embedded tissues. Parvoviruses, including FPL and CPV-2, infect a variety of carnivores, notably domestic and wildlife felids (5, 9). While felids are known to be susceptible to these viruses, the epidemiology and clinical impact in non-domestic species remain poorly understood (7). Infection outcomes vary based on timing and can lead to reduced litter size, severe lymphoid depletion, and classical intestinal disease in older cats, characterized by hemorrhage, villous atrophy, and opportunistic infections (8). Notably, the estimated age of this margay aligns with observations reported in other cases of parvovirus in felids (9).

The virus primarily targets mitotically active cells, notably enterocytes in the intestinal crypts and stem cells in the bone marrow. Parvovirus enters these cells through endocytosis and replicates during the S-phase of the host's DNA replication cycle (6,9). The destruction of enterocytes leads to a significant reduction in the intestinal absorptive surface and contributes to diarrhea, anemia, and hypoproteinemia due to the effusion of tissue fluids and blood into the intestinal lumen (9).

Diagnosis is facilitated by observing viral inclusions and shedding early in the disease course through methods like fecal electron microscopy and virus isolation (8). Additionally, bi-directional transmission between domestic and wild carnivores poses risks, particularly in breeding facilities where outbreaks may occur despite vaccination. The virus is resilient in cool, moist environments, increasing exposure risk for free-ranging carnivores at shared sites (2,8).

There are several pathological differential diagnoses for enteritis in cats. Among infectious causes (feline immunodeficiency virus, coronaviruses, rotaviruses, caliciviruses), feline panleukopenia virus (FPV) is the most prevalent. The main microscopic differential diagnosis in cats is feline leukemia virus (FeLV) infection, which can also cause cryptal necrosis in the intestine (9). FeLV was not tested in this case, so a possible coinfection cannot be entirely ruled out.

However, according to the literature, FeLV is not an endemic disease in wild felid populations (3, 9).

The presence of domestic free-ranging felids in the region, previously documented as potential pathogen reservoirs, highlights the risk of cross-species transmission (4). To the best of our knowledge, there are currently no case reports in the literature documenting parvovirus infection and lesions in margays; although there is serological evidence of exposure to the virus (3).

References

1. Balboni A, Bassi F, de Arcangeli S, Zobba R, Dedola C, Alberti A, Battilani M. Molecular analysis of carnivore Protoparvovirus detected in white blood cells of naturally infected cats. *BMC Vet Res.* 2018 Feb 5; 14(1):41
2. Barrs VR. Feline panleukopenia: a re-emergent disease. *Vet Clin Small Anim.* 2019 Jul 1;49(4):651-70.
3. Blanco K, Peña R, Hernández C, Jiménez M, Araya N, Romero J, Dolz, G. Serological detection of viral infections in captive wild cats from Costa Rica. *Vet Med Int.* 2011 Apr 3; 879029.
4. Conrad J, Norman J, Rodriguez A, Dennis PM, Arguedas R, Jimenez C, Hope JG, Yabsley MJ, Hernandez SM. Demographic and pathogens of domestic, free-roaming pets and the implications for wild carnivores and human health in the San Luis region of Costa Rica. *Vet Sci.* 2021 Apr 20;8(4):65.
5. Decaro N, Buonavoglia C. Canine parvovirus-a review of epidemiological and diagnostic aspects, with emphasis on type 2c. *Vet Microbiol.* 2012 Feb 24; 155(1), 1–12.
6. Parrish C. Chapter 12 – Parvoviridae. In: MacLachlan NJ and Dubovi EJ ed. *Fenner's Veterinary Virology*. 5th ed. Academic Press; 2012.p. 245-257.
7. Steinel A, Parrish CR, Bloom ME, Truyen U. Parvovirus infections in wild carnivores. *J Wildl Dis.* 2001;37(3):594-607.
8. Terio KA, McAloose D, Mitchell E. Chapter 10 - Felidae. In: Terio KA, McAloose D, St. Leger J, editors. *Pathology of Wildlife and Zoo Animals*. Academic Press; 2018. p. 270-271.
9. Uzal FA, Plattner BL, Hostetter JM. Alimentary System. In: Maxie GM, Jubb KVF, ed. *Jubb, Kennedy, and Palmer's Pathology of Domestic Animals*. 6th ed. St. Louis, Missouri: Elsevier; 2016;2. p.153-158.