

## Accepted Manuscript

Title: First report of a naturally patent infection of *Angiostrongylus costaricensis* in a dog

Author: Alejandro Alfaro-Alarcón Vincenzo Veneziano  
Giorgio Galiero Anna Cerrone Natalia Gutierrez Adriana  
Chinchilla Giada Annoscia Vito Colella Filipe Dantas-Torres  
Domenico Otranto Mario Santoro



PII: S0304-4017(15)00399-4  
DOI: <http://dx.doi.org/doi:10.1016/j.vetpar.2015.08.016>  
Reference: VETPAR 7745

To appear in: *Veterinary Parasitology*

Received date: 15-6-2015  
Revised date: 4-8-2015  
Accepted date: 14-8-2015

Please cite this article as: Alfaro-Alarcón, Alejandro, Veneziano, Vincenzo, Galiero, Giorgio, Cerrone, Anna, Gutierrez, Natalia, Chinchilla, Adriana, Annoscia, Giada, Colella, Vito, Dantas-Torres, Filipe, Otranto, Domenico, Santoro, Mario, First report of a naturally patent infection of *Angiostrongylus costaricensis* in a dog. *Veterinary Parasitology* <http://dx.doi.org/10.1016/j.vetpar.2015.08.016>

This is a PDF file of an unedited manuscript that has been accepted for publication. As a service to our customers we are providing this early version of the manuscript. The manuscript will undergo copyediting, typesetting, and review of the resulting proof before it is published in its final form. Please note that during the production process errors may be discovered which could affect the content, and all legal disclaimers that apply to the journal pertain.

**First report of a naturally patent infection of *Angiostrongylus costaricensis* in a dog**

**Alejandro Alfaro-Alarcón<sup>a</sup>, Vincenzo Veneziano<sup>b</sup>, Giorgio Galiero<sup>c</sup>, Anna Cerrone<sup>c</sup>, Natalia Gutierrez<sup>d</sup>, Adriana Chinchilla<sup>d</sup>, Giada Annoscia<sup>e</sup>, Vito Colella<sup>e</sup>, Filipe Dantas-Torres<sup>e,f</sup>, Domenico Otranto<sup>e</sup>, Mario Santoro<sup>c\*</sup>**

<sup>a</sup> *Departamento de Patologia, Escuela de Medicina Veterinaria, Universidad Nacional, Heredia, Costa Rica*

<sup>b</sup> *Department of Veterinary Medicine and Animal Production, University of Naples Federico II, Italy*

<sup>c</sup> *Istituto Zooprofilattico Sperimentale del Mezzogiorno, Via Salute n. 2, 80055 Portici (Naples), Italy*

<sup>d</sup> *Intensivet, Emergency and Critical Care Veterinary Hospital*

<sup>e</sup> *Dipartimento di Medicina Veterinaria, Università degli Studi di Bari, Bari, Valenzano, Italy*

<sup>f</sup> *Department of Immunology, Aggeu Magalhães Research Centre, Oswaldo Cruz Foundation, 50670-420 Recife, Pernambuco, Brazil*

\* *Corresponding author: marisant@libero.it*

*Key words:* abdominal angiostrongyliasis, Angiostrongylidae, pet, zoonotic helminth, reservoir, molecular analyses

**Highlights**

- We describe the first confirmed fatal case of abdominal angiostrongyliasis in a dog.
- *Angiostrongylus costaricensis* identity was confirmed by morphology, histology and molecular characterization of target genes.

- Our data indicate that dogs naturally infected by *A. costaricensis* may shed larvae in their faeces
- This is the first evidence of a naturally infected dog acting as definitive host for *A. costaricensis*.

## ABSTRACT

*Angiostrongylus costaricensis* is the zoonotic agent of abdominal angiostrongyliasis in several countries in North and South America. Rodents are recognized as the main definitive hosts of *A. costaricensis*, but other wildlife species can develop patent infections. Although several human cases have been described in the literature, the role of domestic animals in the epidemiology of the infection is not clear. Here we review the literature available on *A. costaricensis* in mammals and describe the first confirmed fatal case of abdominal angiostrongyliasis in a 4-month-old dog, presented with intestinal perforation, peritonitis and faecal shedding of first-stage larvae. Parasite identity was confirmed by morphology, histology and molecular characterization of target genes. This is the first record of a naturally infected dog acting as a definitive host for *A. costaricensis*. These data suggest that dogs may potentially spread this parasite in urbanized areas.

## 1. Introduction

The genus *Angiostrongylus* (Strongylida, Angiostrongylidae) includes at least 21 species of nematodes infecting the lungs and blood vessels of a variety of mammals including insectivores, rodents, felids and canids (**Anderson, 2000; Spratt, 2015**). *Angiostrongylus costaricensis* is the zoonotic agent of abdominal angiostrongyliasis, which was originally described in 1971 in a human patient from Costa Rica (**Morera and Céspedes, 1971**). Later, *A. costaricensis* was reported in several countries of the Americas, from the United States to Argentina, with the description of nearly 200 human cases occurring within this geographical range (**Graeff-Teixeira et al., 1991; Pena et al., 1995; Romero-Alegría et al., 2014**). Human infections have also been reported from Africa (Zaire) and Europe (France and Spain) (**Romero-Alegría et al., 2014**).

Adult nematodes of *A. costaricensis* reside in the mesenteric arteries of rodents, where females lay their eggs, which hatch in the intestine, and first-stage larvae (L1) are passed in the environment with the faeces (**Anderson, 2000**). To continue the life-cycle, the L1 need to be ingested or actively penetrate the tissue of an intermediate host where they moult twice to the third-stage larvae (L3), which is the infective stage for the definitive hosts (**Thiengo, 1996**). In the definitive host, L3 follow two principal migratory routes after infection: *i*) through the lymphatic/venous-arterial system, or *ii*) through the venous portal system (**Mota and Lenzi 1995, 2005; Spratt, 2015**).

In Costa Rica the most important intermediate host of *A. costaricensis* is the veronicellid slug *Vaginulus plebeius* (**Morera and Ash, 1970; Morera, 1973; Morera et al., 1988**), while at least 12 rodent species have been implicated as definitive hosts (**Morera, 1973; Tesh et al., 1973**), with the cotton rat (*Sigmodon hispidus*) being the most widespread (**Morera and Cepsedes, 1971**). Humans acquire the infection via the consumption of infected molluscs (mainly slugs of the family Veronicellidae), or vegetables contaminated by L3 released in their slime trails (**Ubelaker et al., 1980**). However, the risk of humans to be infected by L3 released in the environment has been considered of minor importance (**Cowie, 2013**) although the snail-to-snail transmission of L3 has been reported as a survival strategy for some nematodes (i.e. *Aelurostrongylus abstrusus* and *Troglostrongylus brevior*) in the same family of *A. costaricensis* (**Colella et al., 2015**). In spite of the zoonotic relevance of *A. costaricensis*, humans represent a dead-end host for this parasite, which does not reach adulthood. In addition, *A. costaricensis* has been reported parasitizing zoo-born siamangs (*Hylobates syndactylus*), night monkeys (*Aotus nancymaae*), free-ranging raccoons (*Procyon lotor*) and opossums (*Didelphis virginiana*) in the United States (**Miller et al., 2006**), although faecal shedding of L1 was not demonstrated for any of these species. However, viable L1 are shed by naturally infected white-nosed coati (*Nasua narica*) (**Monge et al., 1978**) and by captive non-human primates (**Sly et al., 1982; Brack and Schröpel, 1995; Berrocal et al., 1997**). **Arroyo et al. (1998)** described a fatal case of abdominal angiostrongyliasis in a dog, presumptively infected by *A. costaricensis*, but without any parasitological descriptions. Later on, an experimental

infection study suggested that adult dogs may be suitable reservoir hosts in the domestic environment (**Rodriguez et al., 2002**), representing a potential risk of infection for humans.

Here we describe a fatal case of canine abdominal angiostrongyliasis caused by *A. costaricensis* and report, for the first time, the faecal shedding of *A. costaricensis* L1 in a naturally infected dog. Clinical, haematological and pathological data are also reported along with the molecular characterization of *A. costaricensis* specimens collected during post-mortem examination of the same animal.

## **2. Clinical presentation and diagnostic procedures**

On November 2014 a 4-month-old French poodle male weighing 1.1 kg and bought in a pet shop in San José (Costa Rica) was hospitalized in a private veterinary clinic with a history of 7 days of hemorrhagic diarrhoea and occasional vomitus since the first day of its purchase. The dog was cachectic, dehydrated, anaemic and intermittently lethargic. It had a large abdomen with acute abdominal pain and no fever. At the faecal examination the animal scored negative for helminth eggs (by direct faecal smear and flotation methods). Haematology confirmed anaemia (red blood cells: 2.24 M/ $\mu$ L; haematocrit: 15.5%; haemoglobin: 5.1 gr/dL), and moderate neutropenia (2.5 K/ $\mu$ L). Blood biochemistry revealed hypoglycaemia (glucose: 70 mg/dl) and hypoproteinaemia (total protein: 4 gr/dl) and high urea nitrogen (60 mg/dl) and alanine aminotransferase (85 U/L) levels. Radiograph of the abdomen and abdominal ultrasound showed prominent intestinal distension with abundant pneumo-faecal material in the large intestine. A radiopaque image resembling intussusception with intestinal obstruction was also observed in the caudal dextral quadrant of the abdomen. The dog received symptomatic treatment and fluid therapy. At the exploratory laparotomy, necrotic ileocaecal lesions were observed along with intestinal perforation of the distal ileum. The liver showed a yellowish pale discoloration. A resection (approximately 6 cm in length) around the ileal lesion and subsequent anastomosis was performed. The following day, the general condition degenerated and the dog died within 48 h after the surgery.

### *2.1 Anatomopathological findings*

Post-mortem examination performed at the Veterinary School of the National University of Costa Rica revealed the presence of suppurative exudate (about 25 ml) in the abdominal cavity. The abdominal wall had small aggregates of fibrin with associated peritonitis. The lungs, liver, kidneys and spleen were congested. The intestinal serosa (mainly at the ileocaecal junction) was focally thickened with presence of greyish tissue areas and multifocal fibrin aggregation. Mesenteric lymph nodes were enlarged to twice the normal size and haemorrhagic (Fig. 1). The intestinal mucosa was eroded with multifocal petechial and a slightly presence of fibrin. Mesenteric arteries were dilated by adult parasites. Coprological examination performed by Baermann test on faeces collected at necroscopy revealed the presence of nematode larvae. Histopathologically, the intestinal mucosa showed segments of massive coagulative necrosis in association with degenerated nematode larvae and eggs. The lamina propria was diffusely thickened by profuse inflammatory infiltrate composed of large amounts of macrophages with presence of epithelioid macrophages, neutrophils, lymphocytes, plasma cells and eosinophils (Figs. 2, 3). Inflammatory infiltrates extended through the mucosa, the *muscularis externa*, serosa and the associated adipose tissue. Moderate fibrosis of the submucosa was present at some parts of the ileum. Transmural necrotizing pyogranulomatous and eosinophilic inflammation was more prominent at the terminal part of the ileum (Fig. 2). Sections of nematodes in different stages of development were observed in the superficial mucosa, lamina propria, submucosa, *muscularis externa*, and serosa of the intestine (Figs. 2,3) Adipose tissue and mesenteric lymph nodes were associated with prominent eosinophilic infiltrates and multifocal multinucleated foreign body type multinucleated giant cell with up to 12 nuclei. The liver showed several foci of granulomatous inflammation associated with nematode sections. Adult nematodes were also detected in the lumen of dilated mesenteric arteries, occluding partially or completely the arterial lumen, featured by granulomatous and eosinophilic perivasculitis with moderate thickening of endothelium and tunica media. Adult nematodes from mesenteric arteries were stored in 70% ethanol and clarified in lactophenol to be identified. Adult worms and L1 obtained by Baermann technique were morphologically identified as *A. costaricensis* based on the

species-specific features described in **Morera and Céspedes (1971)**, and **Rebello et al. (2013)**. Histopathologically, characteristics of nematode sections obtained from the ileum at laparoscopy were compatible with those of *A. costaricensis* extracted from vessels as described in **Graeff-Teixeira et al. (1991)**.

## 2.2 Molecular analyses

The nematode identity was confirmed molecularly by specific amplification of 12S and 18S gene fragments according to previously described methodologies (**Patterson-Kane et al., 2009; Otranto et al., 2011**). Briefly, following genomic extraction from a single specimen using a commercial kit (DNeasy Blood & Tissue Kit, Qiagen, GmbH, Hilden, Germany), 12S (~300 bp) and 18S (~1700 bp) gene fragments were amplified and amplicons were resolved in (2%) agarose gel, purified and sequenced directly in an automated sequencer (ABI-PRISM 377). Sequences were determined from both strands and compared with those available in GenBank™ dataset by Basic Local Alignment Search Tool (BLAST - <http://blast.ncbi.nlm.nih.gov/Blast.cgi>) (**Altschul et al., 1997**). The BLAST analysis of the 12S and 18S sequences produced here showed 96% and 100% homology, respectively, to those available in GenBank™ (Accession number: LK939409 for 12S, LK942974 for 18S).

## 3. Discussion

The results of this study indicate, for the first time, that dogs naturally infected by *A. costaricensis* may shed larvae in their faeces, therefore acting as a definitive host for this nematode. Although *A. costaricensis* L1 were already found in the faeces of an experimentally infected dog (**Rodriguez et al., 2002**), data on the role of this animal as a spreader of the infection has never been demonstrated under natural conditions. To date, a variety of mammalian species (e.g., non-human primates, raccoons, opossum and procyonids) have been involved as dead-end hosts in the life-cycle of *A. costaricensis* and therefore this nematode may represent a threat for wildlife animals (**Miller et al., 2006**).

The severity of the clinical presentation in the dog herein observed was not consistent with the clinical signs described in a previous case (**Rodriguez et al., 2002**). This apparent difference in clinical presentation might be due to the fact that the dog here examined was much younger than that reported by **Rodriguez et al. (2002)** and consequently a juvenile animal may be more susceptible to the infection by *A. costaricensis*. This hypothesis is also supported by the case report of a 9-month-old puppy presumptively infected by *A. costaricensis* that displayed a severe clinical presentation characterized by abdominal pain and anorexia (**Arroyo et al., 1988**).

From an epidemiological standpoint, the identification of dogs as definitive hosts for *A. costaricensis* and the occurrence of L1 shedding in urbanized area may be of public health concern. Indeed, the presence of rodents, slugs and snails in the peridomestic area represents a risk for dog to acquire infections, and, eventually, to human beings.

In addition, this is the first molecularly confirmed case of a dog naturally infected by *A. costaricensis* and indicating that this species of animals may act as a reservoir host in the domestic environment. Additional studies are required to ascertain the role of dogs in the epidemiology of *A. costaricensis* in areas where this zoonotic nematode is endemic.

### **Acknowledgments**

Authors thank Mike Kinsella (HelmWest Laboratory, USA) for English revision of the manuscript.

### **References**

- Altschul, S.F., Madden, T.L., Schäffer, A.A., Zhang, J., Zhang, Z., Miller, W., Lipman, D.J., 1997. Gapped BLAST and PSI-BLAST: a new generation of protein database search programs. *Nucleic Acids Res.* 25, 3389–3402.
- Anderson, R.C., 2000. *Nematode Parasites of Vertebrates: their Development and Transmission*. CABI International, Wallingford (UK), 650 pp.



Arroyo, R., Rodriguez, F., Berrocal, A., 1988. Angiostrongilosis abdominal en *Canis familiaris*. Parasitol. Dia 12, 181-185.

Berrocal, A., Arroyo, R., Bulgarelli, G., Valverde, A., 1997. Abdominal angiostrongyliasis in a spider monkey (*Ateles geoffroyi*). Eur. J. Vet. Pathol. 3, 35–37.

Brack, M., Schöpel, M., 1995. *Angiostrongylus costaricensis* in a black-eared marmoset. Trop. Geogr. Med. 47, 136–138.

Colella, V., Giannelli, A., Brianti, E., Ramos, R.A., Cantacessi, C., Dantas-Torres, F., Otranto, D., 2015. Feline lungworms unlock a novel mode of parasite transmission. Sci. Rep. 5, 13105; doi: 10.1038/srep13105.

Cowie, R.H., 2013. Pathways for transmission of angiostrongyliasis and the risk of disease associated with them. Hawaii J. Med. Public Health 72, 70–74.

Graeff-Teixeira, C., Camillo-Coura, L., Lenzi, H.L., 1991. Histopathological criteria for the diagnosis of abdominal angiostrongyliasis. Parasitol. Res. 77, 606-611.

Miller, C.L., Kinsella, J.M., Garner, M.M., Evans, S., Gullett, P.A., Schmidt, R.E. 2006. Endemic infections of *Parastrongylus* (= *Angiostrongylus*) *costaricensis* in two species of nonhuman primates, raccoons, and an opossum from Miami, Florida. J Parasitol. 92(2), 406-408.

Monge, E., Arroyo, R., Solano, E., 1978. A new definitive natural host of *Angiostrongylus costaricensis* (Morera and Cespedes 1971). J. Parasitol. 64, 34.

Morera, P., 1973. Life history and redescription of *Angiostrongylus costaricensis* Morera and Céspedes, 1971. Am. J. Trop. Med. Hyg. 22, 613–621.

Morera, P., Andrews, K.L., Rueda, A.D., 1988. The intermediate host of *Angiostrongylus costaricensis* in Honduras. Rev. Biol. Trop. 36, 575–576

Morera, P., Ash, L.R., 1970. Investigación del huésped intermediario de *Angiostrongylus costaricensis* (Morera y Céspedes, 1971). Bol. Chil. Parasitol. 25, 135.

Morera, P., Céspedes, R., 1971. *Angiostrongylus costaricensis* n. sp. (Nematoda: Metastrongyloidea), a new lungworm occurring in man in Costa Rica. Rev. Biol. Trop. 18, 173-185.

Mota, E.M., Lenzi, H.L., 1995. *Angiostrongylus costaricensis* life cycle: a new proposal. Mem. Inst. Oswaldo Cruz 90, 707–709.

Mota, E.M., Lenzi, H.L., 2005. *Angiostrongylus costaricensis*: complete redescription of the migratory pathways based on experimental *Sigmodon hispidus* infection. Mem. Inst. Oswaldo Cruz 100, 407–420.

Otranto, D., Brianti, E., Dantas-Torres, F., Weigl, S., Latrofa, M.S., Gaglio, G., Cauquil, L., Giannetto, S., Bain, O., 2011. Morphological and molecular data on the dermal microfilariae of a species of *Cercopithifilaria* from a dog in Sicily. Vet. Parasitol. 182, 221–229.

Patterson-Kane, J.C., Gibbons, L.M., Jefferies, R., Morgan, E.R., Wenzlow, N., Redrobe, S.P., 2009. Pneumonia from *Angiostrongylus vasorum* infection in a red panda (*Ailurus fulgens fulgens*). J. Vet. Diagn. Invest. 21, 270–273.

Pena, G.P., Andrade-Filho, J., de Assis, S.C., 1995. *Angiostrongylus costaricensis*: first record of its occurrence in the state of Espírito Santo, Brazil, and a review of its geographic distribution. Rev. Inst. Med. Trop. Sao Paulo 37, 369–374.

Rebello, K.M, Menna-Barreto, R.F.S., Chagas-Moutinho, V.A., Mota, E.M., Perales, J., Neves-Ferreira, A.G.C., Oliveira-Menezes, A., Lenzi, H., 2013. Morphological aspects of *Angiostrongylus costaricensis* by light and scanning electron microscopy. Acta Trop. 127, 191-198.

Rodriguez, R., Agostini, A.A., Porto, S.M., Olivaes, A.J.O., Branco, S.L., Genro, J.P., Laitano, A.C., Maurer, R.L., Graeff-Teixeira, C., 2002. Dogs may be a reservoir host for *Angiostrongylus costaricensis*. Rev. Inst. Med. Trop. S. Paulo 44, 55-56.

Romero-Alegría, A., Belhassen-García, M., Velasco-Tirado, V., Garcia-Mingo, A., Alvela-Suárez, L., Pardo-Lledias, J., Cordero Sánchez, M., 2014. *Angiostrongylus costaricensis*: systematic review of case reports. Adv. Infect. Dis. 4, 36-41.

Sly, D.L., Toft II, J.D., Gardiner, C.H., London, W.T., 1982. Spontaneous occurrence of *Angiostrongylus costaricensis* in marmosets (*Saguinus mystax*). Lab. Anim. Sci. 32, 286–288.

Spratt, D.M., 2015. Species of *Angiostrongylus* (Nematoda: Metastrongyloidea) in wildlife: A review. Int. J. Parasitol. Parasites Wildl. 4, 178-189.

Tesh, R.B., Ackerman, L.J., Dietz, W.H., Williams, J.A., 1973. *Angiostrongylus costaricensis* in Panama. Report of the prevalence and pathologic findings in wild rodents infected with the parasite. Am. J. Trop. Med. Hyg. 22, 348–356.

Thiengo, S., 1996. Mode of infection of molluscs with *Angiostrongylus costaricensis* larvae (Nematoda). Mem. Inst. Oswaldo Cruz 91, 277-288.

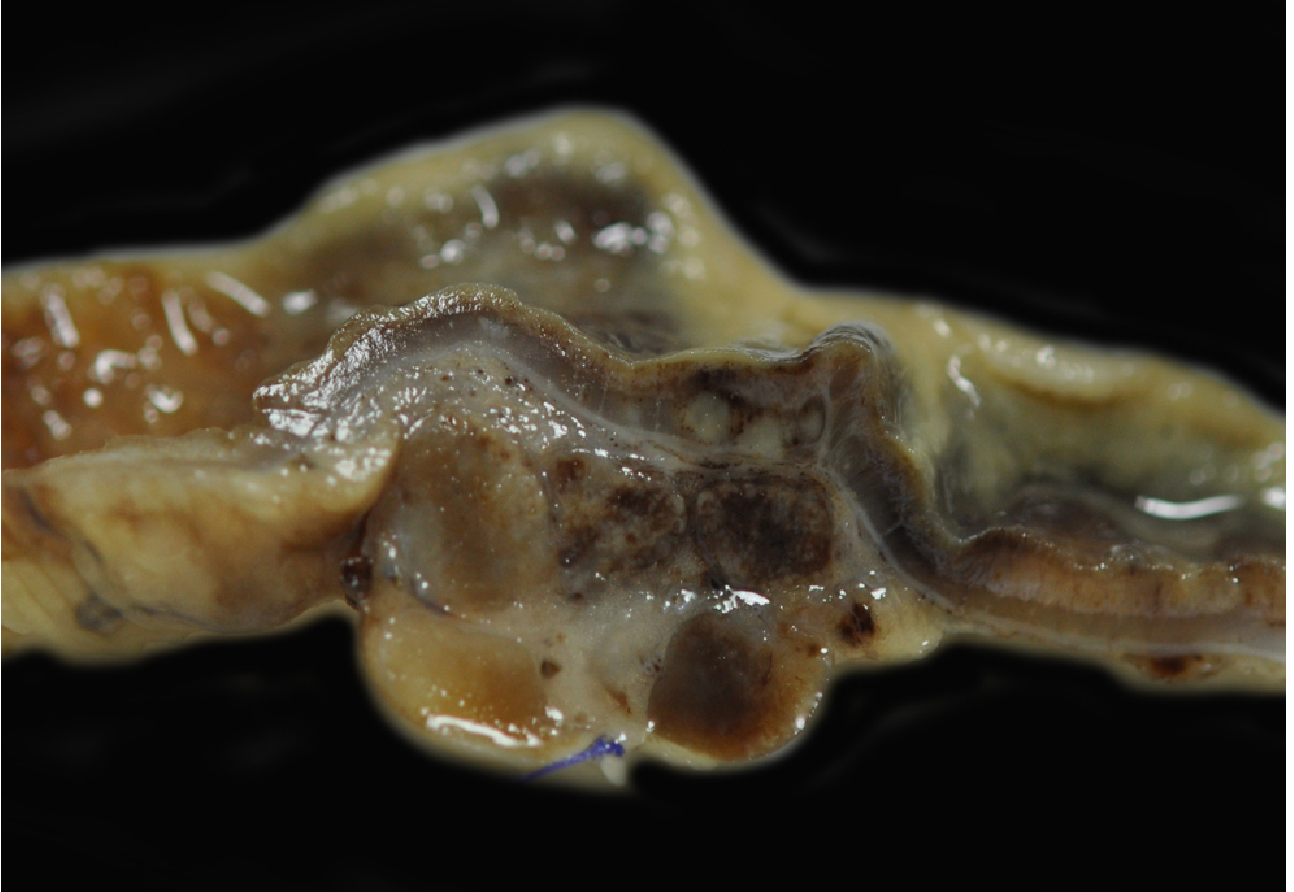
Ubelaker, J.E., Bullick, G.R., Caruso, J., 1980. Emergence of third-stage larvae of *Angiostrongylus costaricensis* Morera and Cespedes 1971 from *Biomphalaria glabrata* (Say). J. Parasitol. 66, 856–857.

#### Figure legends

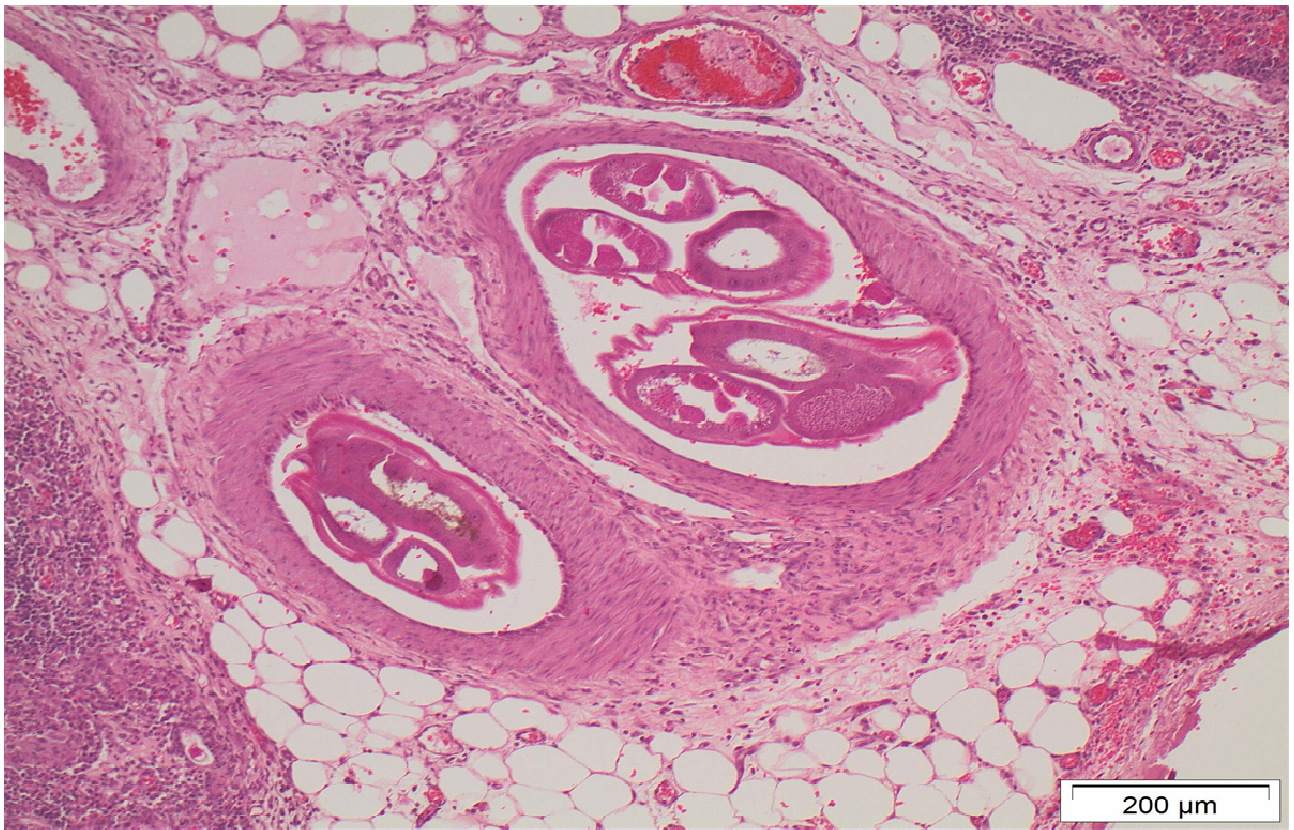
Fig. 1. Enlarged mesenteric lymph nodes and iliocaecal mucosa with multifocal areas of haemorrhage.

Fig. 2. Cross sections of adult worms in the mesenteric artery of the iliocaecal segment; pyogranulomatous inflammation at the intestinal serosa is evident. HE.

Fig. 3. Migration of larvae of *A. costaricensis* (arrow) within the ileal wall in association with granulomatous inflammation (asterisk). HE.

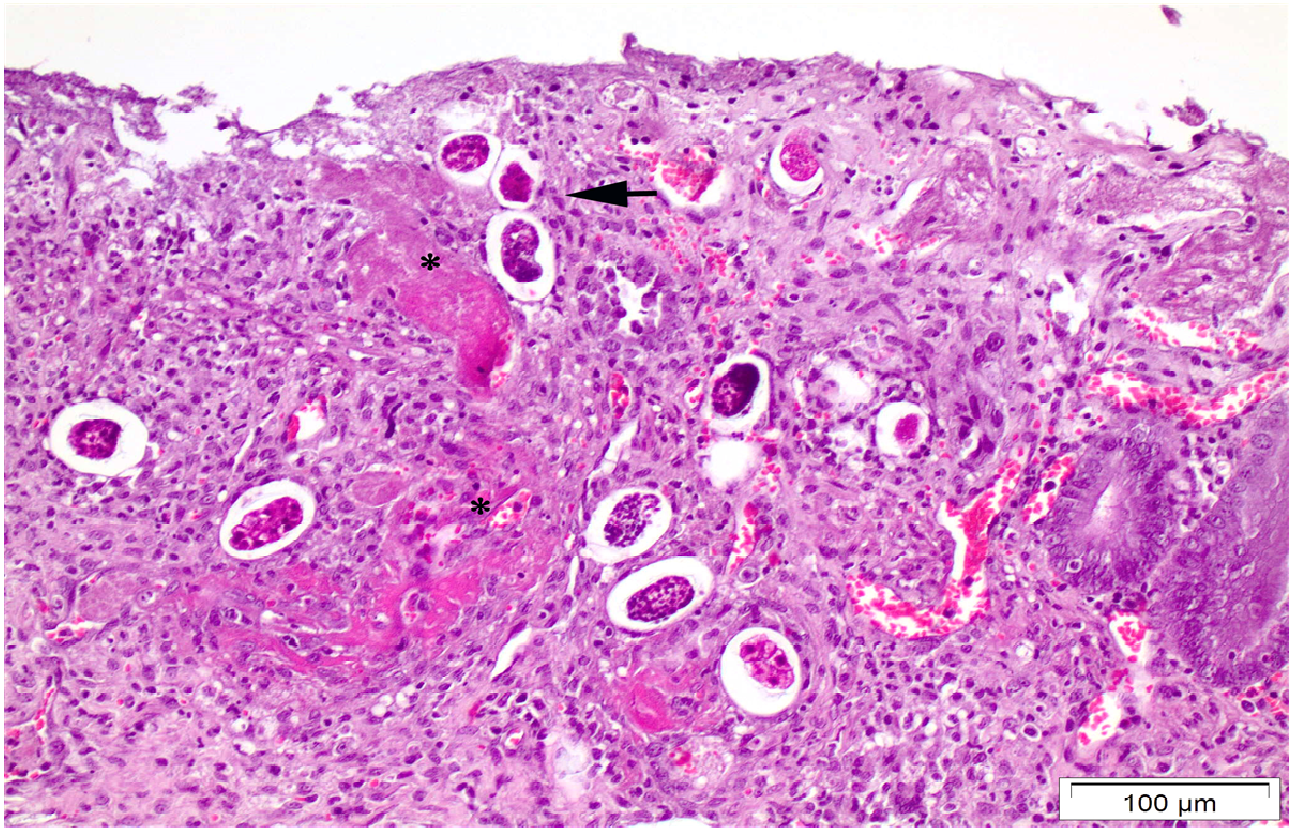


Fig\_1 .



Fig\_2 .





Fig\_3 .